

CASE REPORT

Preventing Progressivity in Becker Muscular Dystrophy Patient: A Rare Case Report

Agatha Wilda Yoanika Prameswari¹, Desy Kurniawati Tandiyo^{1,2}

¹ Indriati Hospital Sukoharjo, Indonesia

² Department of Physical Medicine and Rehabilitation, Faculty of Medicine Sebelas Maret University Surakarta, Sebelas Maret University Hospital Sukoharjo, Indonesia

ABSTRACT

Background: Becker muscular dystrophy is a rare muscle weakness caused by dystrophic gene mutation. Symptoms start to appear after 5-year-old and often begin with weakness in the proximal. Exercise therapy is still a controversial issue, whether it can be beneficial or worse off the disease.

Case Description: An 18-year-old male came with weakness in both legs for three years. This patient was diagnosed with BMD based on examination, elevated levels of creatine kinase (CK), and weakness in right femoral nerve showed on electromyography (EMG). The goal of therapies was to prevent the progression of symptoms. Therapies included range of motion (ROM) exercises, strengthening exercises, and neuromuscular electrostimulation (NMES) in both legs, scheduled once a week for 12 weeks.

Result: After twelve weeks of therapies, patient showed no differences in ROM and manual muscle testing (MMT) compared to when therapies began. In this study, the combination of exercise therapies and NMES did not worsen the symptoms.

Conclusion: In this study, after three months of therapies and evaluation of joint movement and muscle strength, the patient still can do his activity as before therapies.

Keywords: Becker muscular dystrophy, manual muscle testing, rehabilitation, strengthening exercise, range of motion exercises, neuromuscular electrostimulation

ABSTRAK

Latar Belakang: Becker muscular dystrophy merupakan kelemahan otot akibat mutasi gen distrofi dengan insidensi cukup jarang. Kelemahan otot mulai muncul pada usia diatas 5 tahun, sering diawali dengan kelemahan di proksimal. Pemberian latihan masih menjadi perdebatan, apakah memang bisa bermanfaat untuk pasien atau malah mempercepat progresifitas penyakit

Ilustrasi kasus: Kami laporkan laki-laki 18 tahun dengan kelemahan anggota gerak bawah dengan onset 3 tahun. Pasien didiagnosis BMD berdasarkan klinis dan peningkatan kadar creatine kinase (CK) serta electromyography (EMG) yang menunjukkan kelemahan nervus femoralis kanan. Pasien mendapat terapi rehabilitasi yang bertujuan untuk mencegah progresifitas penyakit. Terapi dijadwalkan satu minggu sekali selama 3 bulan berupa range of motion (ROM) exercises, strengthening exercises, dan neuromuscular electrostimulation (NMES) di kedua ekstremitas bawah.

Hasil: Evaluasi dilakukan setelah 3 bulan terapi dengan membandingkan ROM dan manual muscle testing (MMT) sebelum dan sesudah terapi. Dari hasil penilaian tidak terdapat perbedaan ROM dan MMT. Dalam kasus ini, terapi latihan dan NMES tidak memperparah keluhan.

Kesimpulan: Setelah 3 bulan dilakukan terapi rehabilitasi dan evaluasi gerak sendi dan kekuatan otot, pasien masih dapat melakukan aktivitas seperti sebelum terapi.

Kata kunci: Becker muscular dystrophy, manual muscle testing, rehabilitation, strengthening exercise, range of motion exercises, neuromuscular electrostimulation

Correspondent Detail:

Agatha Wilda

Indriati Hospital

Sukoharjo, Indonesia

Email: agathawilda@gmail.com

INTRODUCTION

Becker muscular dystrophy (BMD) is a genetic disease caused by mutation of the dystrophin gene due to defects in the Xp21.2 chromosome, inherited by X-linked recessive.¹ BMD is a slowly progressive weakness from proximal muscle, especially in limb-girdle. It also comes with calf pseudohypertrophy.^{2,3} BMD patients

are rarer than duchenne muscular dystrophy (DMD) and most of them are males.⁴ Tests can be done to confirm diagnosis such as creatine kinase (CK), deoxyribonucleic acid (DNA) genomic mutation analysis, electromyography (EMG), and muscle biopsy.^{5,6} BMD is a disease in which symptoms getting worse over time, so the goals of therapy are to reduce symptoms and prevent progressive symptoms.¹ Planning therapy requires the provision of comprehensive and individually-tailored.⁷ Rehabilitation programs, especially exercise therapy, are still controversial, whether they can be beneficial or worsen the symptoms.⁸ Some studies state that progressive, high-intensity, and resistive exercise is not recommended because it interferes muscle regeneration. Eccentric exercise also damages dystrophin

by excessively increase muscle tension.^{7,8,9} A study showed that BMD patients who received various high-intensity exercises for three years increased mechanical stress, led an increase in CK levels due to excessive muscle damage.¹⁰ A study in mdx mice were given high-intensity exercise also showed functional impairment, characterized by weakness in grip strength and worsened in histopathological imaging.¹¹ On the other hand, exercise therapy was effective in preventing progressivity of muscle weakness and maximizing muscle function. A study of five BMD patients who received low-moderate strengthening exercise and isometric knee exercise three times a week for 40 minutes in 10 weeks showed no decrease in muscle strength after therapy.¹² A study showed that the combination of active, active-assisted, and passive stretching could prevent contractures, especially in the iliotibial band muscles, hip flexors, hamstrings, elbow, and finger flexors.⁵

Besides, neuromuscular electrostimulation (NMES) therapy can be used as an alternative therapy to increase muscle strength in both legs.¹³ A study showed that NMES had significantly improved quadriceps muscle strength compared to the control group.¹⁴ A study by Silva et al. showed that the use of NMES for seven days increased the muscle mass of the lower limbs in non-ambulatory patients with traumatic brain injury.¹⁵ Moreover, NMES has no severe side effects and has a low incidence of muscle pain after therapy.¹³ Repeated exposure to NMES will reduce patient discomfort, muscle fatigue, creatine kinase, and other effects that cause indirect muscle damage.¹⁶ A study in the zebrafish model of DMD performed that

NMES improved muscle structure and did not cause sarcolemma injury.¹⁷ NMES is set to an intensity that the patient can tolerate. The frequency of stimulation ranges from 8-100 Hz, with pulse durations from 250 to 400 μ s.¹⁸ Combining NMES therapy with conventional therapy is more effective than conventional therapy or NMES sham in patients with intensive care unit-acquired weakness.¹⁸ Unfortunately, there is still a lack of studies that discuss the effects of combining exercise therapy and NMES for BMD. Therefore, this study aims to evaluate the effect of using combinations of exercise therapy and NMES in 18-year-old male patients with BMD.

CASE DESCRIPTION

An 18-year-old male came to hospital with weakness in both legs mainly at base of the thigh. This symptoms had been felt for the last three years and had worsened in the last two years. He felt a change in his gait and had difficulty to stand from a sitting position on the floor. Currently, patient could do his normal activities: walked without an assistive gait, rode a motorcycle, and attended lecture face-to-face. He had no difficulty in taking the stairs from the basement to the first floor, but the weakness began when he took the stairs to the second floor, while his classroom was on the third floor. His mother denied any seizures, delayed in motor development or speech-delayed, and history of trauma.

From the physical examination obtained his weight 45 kg and height 169 cm. Examination of manual muscle testing (MMT) of the upper limb was 5555/5555 while the lower limb was

2255/2255. ROM examination can be seen in Table 1.

Table 1. Assessment of patient’s lower extremities

Lower Extremity	Active ROM*	
	Dextra	Sinistra
Hip	Flexion	0-80 ⁰
	Extension	0-15 ⁰
	Abduction	0-30 ⁰
	Adduction	0-20 ⁰
	Exorotation	0-30 ⁰
	Endorotation	0-30 ⁰
Knee	Flexion	0-135 ⁰
	Extension	0-0 ⁰
Ankle	Dorsiflexion	0-20 ⁰
	Plantarflexion	0-45 ⁰
	Eversion	0-25 ⁰
	Inversion	0-35 ⁰

*Range of Motion

When he sat on the floor and started to stand, he had to hold onto the floor and then both knees, as in Figure 1.



Figure 1. Gower’s sign

This condition is called gower’s sign. We also found calf pseudohypertrophy, as seen in Figure 2.

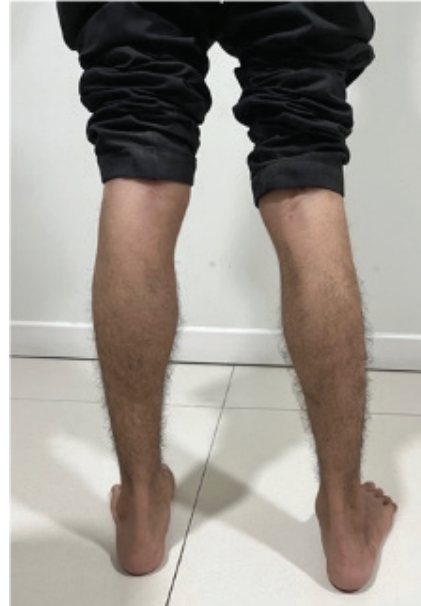

Figure 2. Calf pseudohypertrophy

Chest expansion and count test examinations did not show any lung problems. Sensory examinations did not find abnormalities. Reflex examinations on bicep, tricep, brachioradialis, patella and achilles were normal, meanwhile hoffman and tromner, babinski, chaddock, schaeffer, and oppenheim showed negative reflexes. Defecation and urination showed no abnormalities.

Laboratory examination showed CK level was 963 u/L. The EMG examination conducted on 18/10/2023 showed axonal motor neuropathy in the right femoral nerve.

He regularly took corticosteroid, vitamin B complex and vitamin D from neurology department. Also, he got rehabilitation program once a week for 12 weeks. The goal of therapies was to prevent the progression

of symptoms. Before the program started, he had been told that if he felt tired, he could stop. Also, if he felt pain, he must told to the physicians. He had done ROM exercises and strengthening exercises for 30 minutes, 3 sets of 10 repetitions with 30-seconds break for each movement. First of all, he got ROM exercises involved hip and knee flexors, hip abductors, rotation, hamstring, ankle inversion, eversion, dorso flexors, and plantar flexors. Low-moderate intensity strengthening exercises included isometric strengthening exercises and concentric exercises. Isometric strengthening involved hip flexors, extensors, adductors, abductors, knee flexors, extensors, ankle plantar flexors, and dorso flexors. Concentric exercises involved hip abductors, knee flexors, and heel-raised. After therapy, he got NMES with a frequency of 20-50 Hz amplitude at 1:1:1:6 in both quadriceps muscles for 20 minutes.

RESULT

The evaluation was done after the patient underwent therapy for 12 weeks by comparing ROM and MMT of lower limb muscles before and after the therapy. ROM remained the same, as seen in Table 1, and MMT also did not change. He said that he could still done his activities after exercises, and his weakness did not worsen. In this case, rehabilitation programs did not worsen the symptoms, especially in joint movement and muscle strength. These results showed that patient could return to his daily activities with the help of surrounding environmental modifications.

DISCUSSION

The patient was an 18-year-old male with weakness in both legs. There are studies that explain clinical symptoms of BMD can appear after 5 years old and begin to lose the ability to walk after 15 years old.^{2,19} The incidence of BMD is 1.53–3.6 in every 100,000 men worldwide, three times lower than DMD.²⁰ The prevalence of BMD in men is higher than women. Diagnosing BMD in women tends to be more difficult due to its symptoms that are often absence or milder. BMD is inherited from X-linked recessive family with defect of the Xp21.2 chromosome that caused mutation of the dystrophy gene.¹ 65% to 70% of BMD cases are due to exon deletion, and 5% to 10% are caused by the duplication of exons in the X.^{1,2} Men who inherit this genetic trait will show significant symptoms, whereas in female carriers, the onset will depend on the pattern of X's inactivation.²¹

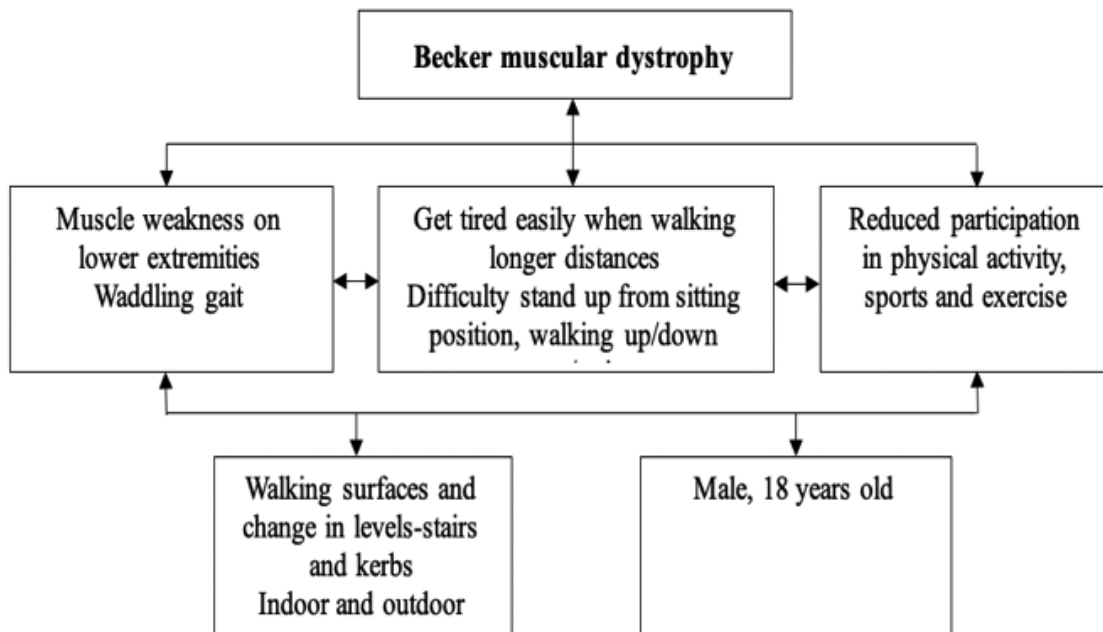
Patient denied family history of muscle weakness, neither from his father's nor mother's families. A study showed that genetic abnormalities in BMD patients can be inherited from the carrier mother (heterozigots for pathogenic variations) or de novo. In the case of de novo mutations, one of the parents may be carrying germinal mosaicism (his gamet population with and without pathogen variations), which is associated with a risk of recurrence in the offspring.⁶ The limitations of genetic examination make it difficult for doctor to trace the genetic carrier of the patient.

In this case, patient could do his daily activities: walked without assistive gait, rode a motorcycle, and attended lecture face-to-face. Research had shown that BMD had relatively milder symptoms and slower progression than DMD.¹ This is related to the dystrophin mutation. In BMD, there is an in-frame mutation that allows the translation of several dystrophins, whereas in DMD, the mutation interferes with the reading frame, making lack of dystrophin and causing more severe symptoms.¹⁹

For the last 2 years, the patient easily got tired, especially when he walked in a long distances or took the stairs. He also felt a change in his gait and difficult to stand from a sitting position on the floor (Figure 1.). We found limitation of joint movement and muscle

strength weakness for both legs. MMT of both legs were 2255/2255. His symptoms were related to weakness of the proximal muscles, characterised by the presence of waddling gait, gower’s sign, and difficulty to take the stairs.¹ Waddling gait is caused by bilateral weakness of the gluteus muscles, which causes gluteus and waist swing to the right and left excessively when walking.¹ Gower’s sign is caused by the pelvic muscle and proximal lower extremity muscle weaknesses, making it difficult for the patient to stand.² We also found calf pseudohypertrophy (Figure 2.), which is a patognomic sign of BMD. Calf pseudohypotrophy is formed as a result of a lack of dystrophins, which causes muscles easier to damage, so that muscle tissue is replaced by fibrosis and fat tissue.²

Graphic 1. International Classification of Functioning, Disability and Health (ICF) of BMD.



Diagnosing BMD is based on the onset and progression of clinical symptoms and examinations, such as CK levels, EMG, and histopathological imaging, with or without a family history of muscle weakness.²² In this patient, CK level was 963 u/L, increased five times from reference value (<190 u/L). A study state that CK levels can be used as an easy, specific, and inexpensive screening for muscular dystrophy. The increase in CK level indicates necrosis and muscle injury.²³ In DMD and BMD cases, the increase in CK levels can reach >511,5 u/L. CK level in BMD is usually five times higher or more. However in DMD, CK level is higher than in BMD, ranging between 5,000 and 150,000 u/L.²³

We found axonal motor neuropathy in the right femoral nerve on EMG. EMG is a test that measures electrical currents generated in muscles during contractions that represent neuromuscular activity. EMG can be used to distinguish between neurogenic diseases and myopathy, as well as neuromuscular transmission disorders.²⁴

In this study, patient performed low-moderate intensity ROM and strengthening exercises, included isometric and concentric exercises, combined with NMES. Rehabilitation programs aim to maintain strength, function, and independence. Strengthening exercise is an essential tool to maintain strength in most chronic diseases. While still being debated, this exercise is as beneficial as able-bodied, and significant concern about overworking weak muscles prevents widespread acceptance by clinicians.^{8,12} Patient said that he did not experience excessive fatigue and could still do his daily activities after therapy. This is in line

with a study conducted by Jensen et al on five BMD patients who received low-moderate intensity strengthening and isometric knee exercise three times for 40 minutes in 10 weeks, which showed no decrease in muscle strength after intervention.¹² It is not recommended for patients with muscular dystrophy to overuse or fatigue their muscles.¹² Although the effect over a longer period is uncertain, a recent investigation showed that myopathic individuals and controls responded similarly to an acute bout of eccentric contractions. There is evidence that a high-strengthening exercise program does not provide any additional benefits to strength compared to a moderate-strengthening exercise program.¹⁰ A study on mdx mice that underwent high-intensity exercise showed functional impairment characterized by decreased grip strength and worsening muscle histopathological imaging.¹¹ After exercise therapies, patient received NMES. Muscle strengthening from electrical muscle stimulation showed good results in patients with muscle weakness. NMES uses a lightweight stimulator unit and a skin electrode to produce controlled and comfortable muscle contractions. NMES can provide improvements in muscle function, exercise capacity, and quality of life especially in patients with muscle weakness.¹³ The effect was considered due to maintaining protein synthesis in muscles rather than preventing protein breakdown. At the same intensity, NMES activates more type II (fast twitch) muscle fibers than volitional training exercises. Increased force output requires Type II fibers, and activating them may result in better functional performance.¹⁶ A study showed that NMES significantly improved quadriceps muscle strength compared to the

control group.¹⁴ The frequency of stimulation ranges from 8-100 Hz with pulse durations from 250 to 400 μ s.¹⁸ Tracking alternating amplitudes during therapy ensures the depolarization of different motor units on several motoric units and improves muscle adaptation during therapy.¹⁶ However, when using electrical stimulation more attention should be put for patients with low muscle fiber counts since it causes all muscle fibers to twitch simultaneously, which may accelerate degeneration. For this reason, patients with muscle strength below three should not use current types that will cause fatigue.²⁶ In this study, patient received NMES with a frequency of 20-50 Hz amplitude 1:1:1:6 that had been adjusted to patient tolerance so that after therapy, patient did not feel excessive fatigue or pain. After 12 weeks, the patient's ROM and MMT did not change from before the therapies. This result showed that combination therapy did not worsen the symptoms as long as it still under patient's tolerance.

CONCLUSION

BMD is a disease caused by a dystrophin gene mutation that leads to progressive muscle weakness. Twelve weeks of rehabilitation program, which included ROM exercises, strengthening exercises, and NMES in patients, had showed no worsening of symptoms so patient could still performed his daily activities even with some adjustments due to his condition. Periodic rehabilitation therapy and evaluation should be carried out to maintain joint movement and muscle strength.

REFERENCES

1. Thada P, Bhandari J, Umapathi K. Becker muscular dystrophy. StatPearls Publishing;2022.
2. Flanigan KM. Duchenne and Becker muscular dystrophies. *Neurologic clinics* 2014; 32(3):671-88.
3. Salari N, Fatahi B, Valipour E, Kazeminia M, Fatahian R, Kiaei A, et al. Global prevalence of Duchenne and Becker muscular dystrophy: a systematic review and meta-analysis. *Journal of orthopaedic surgery and research* 2022;17(1):1-12.
4. Mah JK, Korngut L, Dykeman J, Day L, Pringsheim T, Jette N. A systematic review and meta-analysis on the epidemiology of Duchenne and Becker muscular dystrophy. *Neuromuscular Disorders* 2014;24(6):482-91.
5. Wein N, Alfano L, Flanigan KM. Genetics and emerging treatments for Duchenne and Becker muscular dystrophy. *Pediatric Clinics of North America*. 2015; 62(3):723-42.
6. Magot A, Wahbi K, Leturcq F, Jaffre S, Pereon Y, Sole G. Diagnosis and management of Becker muscular dystrophy: the French guidelines. *Journal of Neurology* 2023;270(10):4763-81.
7. Lanza G, Pino M, Fisicaro F, Vagli C, Cantone M, Pennisi M, et al. Motor activity and Becker's muscular dystrophy: lights and shadows. *The Physician and Sportsmedicine* 2020;48(2):151-60.
8. Gianola S, Castellini G, Pecoraro V, Monticone M, Banfi G, Moja L. Effect of muscular exercise on

- patients with muscular dystrophy: a systematic review and meta-analysis of the literature. *Frontiers in neurology* 2020;11:958.
9. Tramonti C, Rossi B, Chisari C. Extensive functional evaluations to monitor aerobic training in Becker Muscular Dystrophy: A case report. *European journal of translational myology* 2016;26(2).
 10. Gencer G, Toraman N. Long-term intense exercise training in becker muscular dystrophy: 3-year follow-up. *Neurological Sciences and Neurophysiology* 2020;37(1):38-39.
 11. Zelikovich A, Quattrocelli M, Salamone I, Kuntz N, McNally E. Moderate exercise improves function and increases adiponectin in the mdx mouse model of muscular dystrophy. *Scientific reports* 2019;9(1):5770.
 12. Jensen BR, Berthelsen MP, Husu E, Christensen SB, Prahm KP, Vissing J. Body weight-supported training in Becker and limb girdle 2I muscular dystrophy. *Muscle & nerve* 2016;5(2): 239-43.
 13. Jones S, Man W, Gao W, Higginson I, Wilcock A, Maddocks M. Neuromuscular electrical stimulation for muscle weakness in adults with advanced disease. *Cochrane database of systematic reviews* 2016:10.
 14. Akagi R, Miyokawa Y, Shiozaki D, Yajima Y, Yamada K, Kano K, et al. Eight-week neuromuscular electrical stimulation training produces muscle strength gains and hypertrophy, and partial muscle quality improvement in the knee extensors. *Journal of Sports Sciences* 2023;41(24):2209-2228.
 15. Silva P, Cássia M, Livino C, Araujo A, Castro J, Silva V, et al. Neuromuscular electrical stimulation in critically ill traumatic brain injury patients attenuates muscle atrophy, neurophysiological disorders, and weakness: a randomized controlled trial. *Journal of Intensive Care* 2019: 7:1-13.
 16. Glaviano N, Saliba S. Can the use of neuromuscular electrical stimulation be improved to optimize quadriceps strengthening? *Sports health* 2016;8(1):79-85.
 17. Kilroy E, Ignacz A, Brann K, Schaffer C, Varney D, Alrowashed S, et al. Beneficial impacts of neuromuscular electrical stimulation on muscle structure and function in the zebrafish model of Duchenne muscular dystrophy. *Elife* 2022;11:e62760.
 18. Maffiuletti N, Roig M, Karatzan E, Nanas S. Neuromuscular electrical stimulation for preventing skeletal-muscle weakness and wasting in critically ill patients: a systematic review. *BMC medicine* 2013;11:1-10.
 19. Ciafaloni E, Kumar A, Liu K, Pandya S, Westfield C, Fox DJ, et al. Age at onset of first signs or symptoms predicts age at loss of ambulation in Duchenne and Becker Muscular Dystrophy. *Journal of pediatric rehabilitation medicine* 2016;9(1):5-11.
 20. Andrews JG, Wahl RA. Duchenne and Becker muscular dystrophy in adolescents: current perspectives. *Adolescent health, medicine and therapeutics* 2018; Volume 9:53-63.

21. Romitti PA, Zhu Y, Puzhankara S, James KA, Nabukera SK, Zamba GKD, et al. Prevalence of Duchenne and Becker muscular dystrophies in the United States. *Pediatrics* 2015;135(3): 513-21.
22. Domingos J, Sarkozy A, Mariacristina S, Muntoni F. Dystrophinopathies and limb-girdle muscular dystrophies. *Neuropediatrics* 2017;4(04):262-72.
23. Saha S, Joardar A, Roy S, Mondal T, Gangopadhyay G, Haldar D, et al. Serum creatine kinase and other profile of Duchenne muscular dystrophy and Becker muscular dystrophy: A cross-sectional survey in a tertiary care institution at Kolkata. *Chrismed Journal of Health and Research* 2021;8(3):175-81.
24. Hafner P, Phadke R, Manzur A, Smith R, Jaiser S, Schutz P, et al. Electromyography and muscle biopsy in paediatric neuromuscular disorders—Evaluation of current practice and literature review. *Neuromuscular Disorders* 2019;29(1):14-20.
25. Bansal S, Zutshi K, Munjal J. Effect of Neuromuscular Electrical Stimulation Integrated with Closed Kinetic Chain Exercises on Strength of Quadriceps Muscle. *Indian Journal of Physiotherapy & Occupational Therapy* 2020;14:3.
26. Suzuki, T, editor. *Neurological Physical Therapy*. Croatia: InTech Publisher; 2017.p.175-200.